

Conceptual modeling of the subject area 'Aseptic Wound' for AI-based medical systems

Serhii Lupenko^{1,*†}, Michał Tomaszewski^{1,†}, Anna Bryniarska^{1,†}, Andrii Pavlyshyn^{2,†} and Oleksandra Orobchuk^{3,†}

¹ Department of Computer Science, Opole University of Technology, Prószkowska 76 Street, 45-758 Opole, Poland

² Department of General Surgery, Ministry of Health of Ukraine, I. Horbachevsky Ternopil National Medical University, 1 Voli Square, Ternopil, 46001, Ukraine

³ Ternopil Ivan Puluj National Technical University, 56 Ruska str., Ternopil, 46001, Ukraine

Abstract

The study presents a comprehensive methodology for visual assessment of aseptic wounds with the possibility of its application in artificial intelligence (AI) systems for monitoring the wound process. The relevance of the topic is due to the growing number of surgical interventions, war wounds, and man-made injuries that are accompanied by wound formation. The main goal of the article is to develop a conceptual model of the subject area "Aseptic Wound" to support the design of intelligent medical systems, particularly those utilizing deep learning algorithms for image-based diagnosis and wound classification or segmentation. The morphological, planimetric, topographic and color markers of aseptic wounds, which can be used for automated assessment, are analyzed. A structured set of parameters is proposed, which can be integrated into annotated training datasets for machine learning models and has been used to construct a prototype ontology of aseptic wounds. This ontology enables the semantic interpretation and standardization of wound features, facilitating interoperability between clinical data sources and AI systems. The results of the work are the basis for improving the accuracy of clinical diagnosis and individualization of treatment protocols. Moreover, the conceptual model and ontology lay the groundwork for the development of an ontological knowledge base for medical expert systems, which is particularly important in the context of training deep learning models that require well-labeled, semantically rich datasets to achieve high performance and generalizability in clinical practice.

Keywords

aseptic wounds, ontology, conceptual model, visual assessment, artificial intelligence

1. Introduction

The rapid development of digital technologies and artificial intelligence has led to significant transformations in the healthcare sector, including in the diagnosis, treatment and monitoring of patients. In medicine, the use of AI allows for optimizing the provision of medical services, speeding up the process of working with databases, improving the results of diagnosing visual and digital examination results, and facilitating differential diagnosis and the diagnosis process. The use of AI tools is especially relevant in surgery, where a quick and objective assessment of the wound condition can determine the effectiveness of further clinical decisions. However, the issue of visual assessment of different types of wounds and the wound process is still far from ideal and therefore subject to detailed study and research [1].

Today, the number of wound defects (wounds) is growing rapidly, not only due to scientific and technological progress and, as a result, the development of man-made injuries in complex technological industries, but also, unfortunately, due to a sharp increase in the number of military

¹ITTAP'2025: 5th International Workshop on Information Technologies: Theoretical and Applied Problems, October 22-24, 2024, Ternopil, Ukraine, Opole, Poland

^{*}Corresponding author.

[†] These authors contributed equally.

✉ lupenko.san@gmail.com (S. Lupemko); m.tomaszewski@po.edu.pl (M. Tomaszewski); a.bryniarska@po.edu.pl (A. Bryniarska); pavlyshyn.av@gmail.com (A. Pavlyshyn); orobchuko@gmail.com (O. Orobchuk)

ORCID 0000-0002-6559-0721 (S. Lupemko); 0000-0001-6672-3971 (M. Tomaszewski); 0000-0002-3839-459X (A. Bryniarska); 0000-0002-5506-7582 (A. Pavlyshyn); 0000-0002-8340-913X (O. Orobchuk)



© 2025 Copyright for this paper by its authors. Use permitted under Creative Commons License Attribution 4.0 International (CC BY 4.0).

conflicts and wars. In addition, progress in the field of medicine contributes to an increase in the number of types of surgical interventions, changes in their quality, duration, and complexity, which in turn is accompanied by aseptic wounds, without which it is impossible to gain surgical access to tissues. An aseptic wound formed as a result of a planned surgical intervention is an ideal model for analyzing the features of the wound process. It does not contain signs of infection, and its healing occurs under favorable conditions, which allows us to identify typical visual markers of regeneration.

Healing of aseptic wounds by primary tension, without visible cosmetic defects and complications, is one of the important components of successful surgical treatment. Wound assessment is carried out according to a number of parameters that have a clear morphological, topographic, and functional classification. At the same time, digital images obtained with cameras or lidar sensors can serve as a source for building training samples in computer vision systems.

From the perspective of deep learning, the creation of a standardized, semantically rich representation of aseptic wounds is of fundamental importance. Deep learning algorithms, particularly convolutional neural networks (CNNs), require large, well-annotated datasets with consistent feature definitions to effectively learn complex visual patterns [1,2]. However, in clinical contexts, especially in surgical wound analysis, the lack of unified taxonomies and labeled data hampers the development of reliable AI models. By introducing a formal conceptual model of the "Aseptic Wound" domain and constructing an ontology that captures relevant features and their relationships, this work lays the groundwork for creating high-quality datasets that reflect expert knowledge in a structured and machine-readable form. In publication [3] pointed out, the lack of consistent terminology and structured annotations remains a major barrier to the implementation of AI in clinical settings.

Furthermore, the proposed ontology can be used to support explainable AI (XAI) frameworks, enabling clinicians to understand and validate the reasoning behind the system's predictions. According to [4], this is crucial in high-stakes clinical settings, where AI decisions must be transparent and justifiable. By aligning visual parameters with ontological classes and relationships, deep learning models can be trained not only for classification or segmentation tasks but also for semantic reasoning and longitudinal monitoring of wound healing. Thus, this study contributes to bridging the gap between unstructured visual data and structured expert knowledge, facilitating the safe and effective deployment of deep learning tools in surgical care.

In this regard, there is a need to formalize the knowledge of specialists (in particular, surgeons) and develop a standardized set of characteristics of an aseptic wound that will provide a single terminology and be suitable for automated analysis, diagnosis and monitoring - in the form of a computer ontology. The main goal of this article is to develop a conceptual model and ontology of the subject area "Aseptic Wound" that will support the design of intelligent medical systems based on deep learning. This includes the identification and formalization of key morphological, topographic, and visual parameters of aseptic wounds suitable for automated analysis. The outcome of this work serves as a foundation for constructing training datasets, improving diagnostic accuracy, personalizing treatment protocols, and enhancing the integration of ontological knowledge into medical expert systems.

2. Related Works

Previous research in digital medicine and biomedical image analysis has focused on the use of deep learning to identify pathological changes in the skin (e.g., melanoma, pressure ulcers, burns) [5, 6]. A significant part of publications is devoted to the automatic classification of chronic wounds or their healing phases. For example, the Woundontology Consortium (a consortium of ontologists and clinicians) has developed a preliminary structure of the ontology of chronic (including aseptic)

wounds [7]. A formal definition of the wound healing process is provided in the Gene Ontology Term “Wound healing” [8]; and a description of the biomedical ontology covering experimental approaches, including wound research (description of wound assessment protocols and data collection by experts) is presented in [9].

Aseptic wounds have a complex course that depends on a number of factors - clinical, visual, and individual patient characteristics. However, techniques focused on aseptic wounds remain fragmented. There is a lack of systematized approaches to visualizing such wounds, taking into account their specific features (absence of infection, predictability of regeneration phases, controlled conditions of formation). Therefore, an approach that combines clinical relevance and technological implementation for automated assessment of aseptic wounds needs to be improved. And to formalize and structure the knowledge used by medical professionals in the visual assessment of wounds, it is advisable to create an appropriate ontology.

3. Proposed methodology

3.1. Conceptual modeling of the subject area “Aseptic wound”

The conceptual model was built on the basis of the knowledge of experts in the field of surgery through a multi-stage survey. The main stages of modeling were:

1. Defining the goals of the ontology: providing a formalized description of key concepts, processes and signs of aseptic wounds for further use in AI systems.
2. Collection and systematization of concepts: based on the analysis of scientific literature and expert responses, a preliminary list of terms and attributes was formed.
3. Grouping of concepts into classes: all concepts are grouped into logical categories (for example: Wound type, Signs of healing, Visual characteristics, Localization, Stage of the process).
4. Establishment of relationships between concepts: a hierarchy of concepts was formed, as well as semantic relationships such as “part of”, “related to”, “has a feature”.
5. Formalization in the form of a diagram in the Protégé environment that reflects the conceptual structure of the ontology.

Expert knowledge was collected through a structured survey using questionnaires and semi-structured interviews in the following stages (Fig. 1).

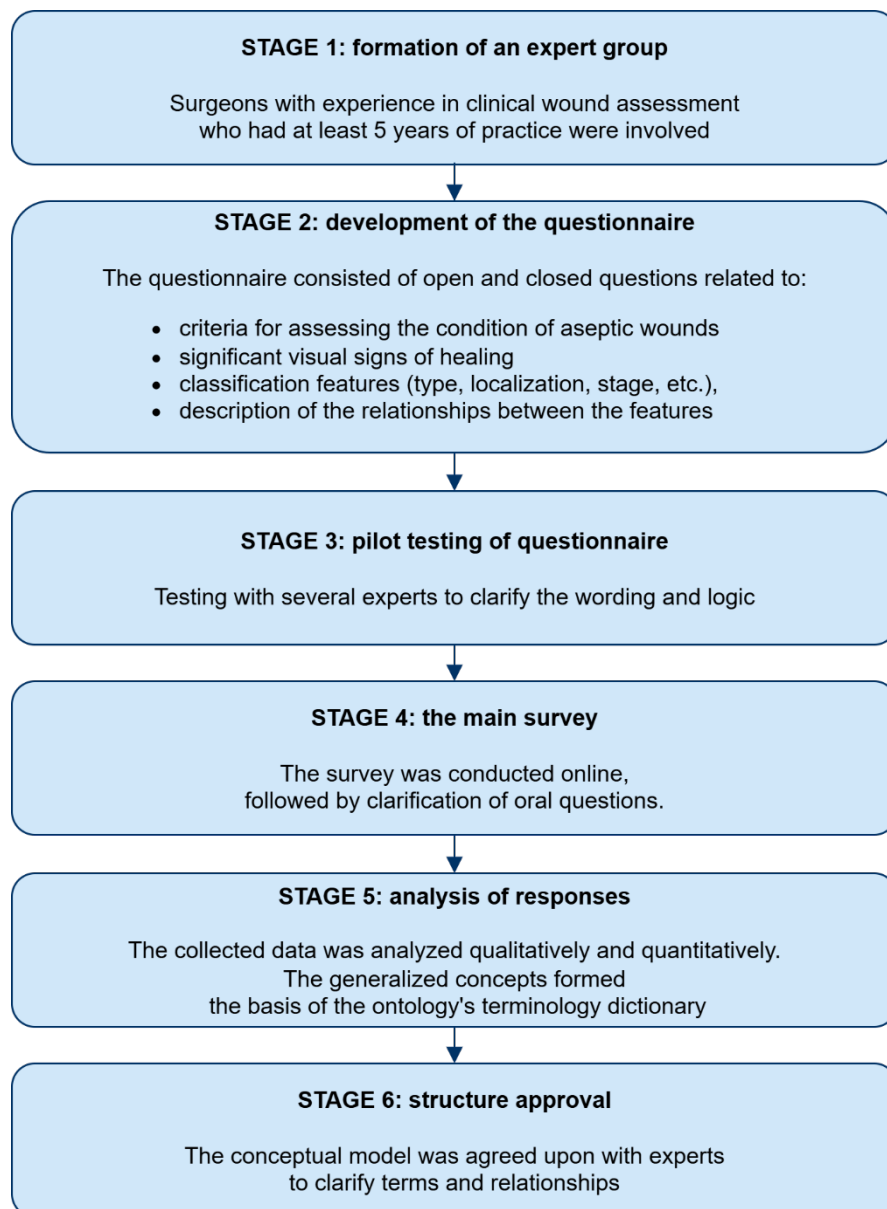


Figure 1: Stages of gathering expert knowledge.

3.2. Formation of a standardized set of aseptic wound characteristics

Wounds are something that is most often encountered not only in the course of their professional activities by specialists in various fields, but also by ordinary people in domestic and non-industrial settings. Let's define what we mean by a wound. A wound is a mechanical injury that results in a disruption of the integrity of the skin, mucous membranes (superficial wounds), and underlying internal organs (deep wounds). The main visual signs of a wound are the presence of damage to the skin or mucous membrane, or a combination of both.

When studying the visual characteristics of wounds, we begin with those that meet all the objective criteria of a 'wound' but exhibit minimal signs of complications such as inflammation, necrosis, or bleeding. Such wounds include the most 'healthy' ones - aseptic, i.e., surgical wounds. Aseptic (surgical) wounds are made by a surgeon under maximally sterile conditions for therapeutic or diagnostic purposes. Aseptic wounds inflicted by medical personnel using specialized surgical instruments (scalpel, surgical saw, scissors, perforators, etc.) may exhibit some visual characteristics of incised wounds: slight tissue separation in the direction of the applied force of the surgical instrument, gaping [10,11].

One of the objectives of our study is to assess the wound and the wound healing process through its visualization followed by AI training. The visualization process is based on images of the wound and surrounding tissues, which are evaluated according to selected criteria. The application of AI enables objective monitoring of the wound healing process in accordance with the wound healing phases and allows for remote adjustment of treatment strategies [12,13].

It should be noted that the visual indicators for identifying the very concept of a wound include the presence of damage to the skin, mucous membranes, or a combination of both. These clinical signs are effectively detected and segmented by AI-based image analysis tools [14], enabling further classification aligned with established medical guidelines. The proposed visual markers for identifying the presence of a wound on the victim's (or patient's) body are as follows – table 1.

Table 1
Visual Markers of the Wound

Visual Markers of the Wound							
Damage	No	Yes					
Skin							
Mucous membranes							
Underlying tissues	Sub- cuta- neous fat	Fascia	Perito- neum	Muscle tissue	Serous- memb- rane		
Underlying internal organs	Brain	Heart	Lungs	Liver	Spleen	Kidneys	Intes- tines

Some of the key criteria for processing images of aseptic wounds and other types of wounds include determining their planimetric characteristics, namely: wound shape, dimensions, perimeter, depth (in 3D), and area. Using digital tools and AI, based on the obtained digital image, we determine the affected surface area by creating a two-dimensional or 3D (with the help of LiDAR sensors) model of the wound contours.

The criteria for planimetric wound assessment include the following indicators – table 2. The specified planimetric parameters will be used not only for aseptic wounds but also for wounds of other types, as they are universal.

Table 2
Planimetric Assessment of the Wound

Characteristic	Digital value, mm		
Shape	linear	arcuate	polygonal
Length			
Width			
Area			

Depth
Perimeter

In addition to the wound's planimetric characteristics, clear visualization and description of its edges are essential, as they serve as one of the indicators for classifying the wound according to widely accepted types. Based on the condition of the wound edges, it can be categorized as incised, puncture, lacerated, crushed, bite, gunshot, etc. Therefore, the characterization of wound edges is very important, and we propose the following visual features – table 3.

Table 3

Visual Markers of Wound Edges

Wound edge characteristic	No	Yes
Smoothness		
Sharpness		
Contouring		

When analyzing the 2D or 3D model of the wound's visual characteristics, determining its anatomical topographical location is extremely important. Accurate wound topography on the patient's body makes it possible to obtain a number of essential anatomical characteristics, such as: the type of underlying tissues directly at the injury site, and the location relative to vital organs and systems (major blood vessels, nerve trunks, organs, etc.). Topographical data also help effectively predict the risk of complications and plan the optimal prevention strategy.

Therefore, to optimize AI performance in the visual assessment of the wound and the overall wound healing process, we propose determining the following anatomical-topographical characteristics of the wound – table 4.

Table 4

Wound Localization Relative to Langer's Lines

Position	No	Yes
Smoothness		
Sharpness		
Contouring		

An important element of the visual assessment of a wound is its relation to Langer's lines. These are imaginary lines that reflect the anatomical structure of the skin, running along the surface and indicating the direction of maximum tension of collagen and elastin fibers in the dermis. They correspond to the orientation of connective tissue fibers. The alignment of a wound parallel to Langer's lines positively affects the speed and quality of healing. Such wounds heal faster and tend to form less visible scars. Conversely, wounds located perpendicular to these lines heal more slowly,

experience tension at the wound edges (negatively affecting healing), and often result in wide, noticeable, and aesthetically unpleasing scars.

Table 5

Anatomical-Topographical Characteristics of the Wound

Anatomical region	No	Yes	Subregions (if applicable)			
Head			Anterior	Posterior surface	Upper	Middle Lower third
Neck			Anterior	Posterior surface	Upper	Middle Lower third
Chest			Anterior	Posterior surface	Upper	Middle Lower third
Upper limb			Anterior	Posterior surface	Hand	Forearm Shoulder
Abdomen			Anterior	Posterior surface	Upper	Middle Lower third
Lower limb			Anterior	Posterior surface	Foot	Lower leg Thigh
Pelvic region			Anterior			Posterior surface
Perineum						

Since wound formation is often accompanied by damage to blood vessels of various types and calibers, it is essential that the visual assessment of the wound includes identification of the type of bleeding – table 6.

Table 6

Wound Characterization by Type of Bleeding

Type of bleeding	No	Yes
Arterial		
Venous		
Capillary		
Parenchymal		

Each type of bleeding has its own visual characteristics that help in its identification, which in turn directly influences the wound healing process, the risk of complications, and the overall treatment strategy.

In addition to determining the visual features of the wound, it is also essential to record the time of wound formation. Documenting when the wound occurred allows the specialist to approximately determine the phase of the wound healing process and the tissue changes in response to injury. Furthermore, the longer a wound remains untreated and without primary surgical care, the more likely it is to become bacterially contaminated.

Determining the time of an aseptic wound is a simpler task, as it is inflicted by a surgeon and precisely recorded in the medical documentation down to the hour and minute. For all other types of wounds, it is recommended to document the time at least approximately. Based on the account of the injured person, witnesses, healthcare workers, or rescue personnel. The following time intervals are proposed for recording the moment of wound occurrence – table 7.

Table 7

Wound Characterization by Time of Occurrence

Time Interval	Yes
Exact time	_____ hours _____ minutes
Up to 1 hour	
Up to 3 hour	
Up to 6 hour	
Up to 12 hour	
Up to 24 hour	
Up to 48 hour	
Up to 72 hour	

In the case of aseptic wounds, all the above-mentioned visual characteristics must of course be assessed first, especially when the analysis is performed shortly after the wound is inflicted.

However, the wound changes over time, and from the moment of tissue damage, a complex process of physiological responses is triggered in the body, aimed at quickly restoring the integrity of the injured area. This regeneration process is known as the wound healing process, and it is characterized by a specific sequence (phases) of reparative processes in the wound, surrounding tissues, and the body as a whole.

During the wound healing process, the visual characteristics of the wound and their markers will naturally evolve, and new ones may appear. Additionally, a number of complications may arise during healing, each with their own distinct visual markers.

From the moment of wound occurrence and throughout the healing process, different types of wound exudates may appear. These may come from the damaged tissues or as a result of complications such as infection. It is proposed to record wound exudates based on the following criteria – table 8.

Table 8

Wound Characterization by Type of Exudate

Type of exudate	No	Yes	Area
-----------------	----	-----	------

Serous exudate
Serosanguinous exudate
Purulent exudate
Seropurulent exudate
Mucous exudate
Fibrinous exudate

Obtaining reliable visual information regarding the presence or absence of wound exudates, along with their qualitative and quantitative characteristics, allows for the use of such findings as diagnostic criteria to form a clear picture of the wound healing process. Whether it is progressing successfully or, on the contrary, complications or infections are developing.

In addition to identifying the above-mentioned types of wound exudates, it is extremely important to learn to visually diagnose the presence of a bacterial biofilm on the wound surface [15]. This formation represents a structured cluster of bacteria covered by a protective extracellular matrix, which ensures their resistance to antibiotics and antiseptics.

The visual indicators of bacterial biofilm on the wound surface include the following characteristics – table 9.

Table 9
Wound Characterization by Type of Bacterial Biofilm

Type of biofilm	No	Yes	Area
Thin transparent bacterial layer			
Thin matte bacterial layer			
Thin gray-white bacterial layer			
Thin yellow bacterial layer			

The presence of the above-mentioned signs on the wound surface indicates the development of complications in the healing process, including: increased inflammation, the spread of infection, the development of resistance to antibiotics and antiseptics, and, as a consequence, the transformation of the wound into a chronic state.

Visual assessment of tissue color in the wound itself and in the surrounding skin also plays a critical role. A physiological (pale-pink) skin color is a diagnostic marker of a healthy state of the body. Any discoloration (pallor, jaundice, cyanosis) may indicate pathological conditions such as anemia, hypoxia, or liver dysfunction. Recent AI-based approaches have emphasized the importance of accurate color calibration in wound image analysis. One smartphone-based system achieved improved segmentation performance when a calibration chart was used to standardize color and measurement across images, enabling more consistent identification of epithelialization (pink), granulation (bright red or pale pink), and necrosis (black or white tissue) [16,17]. Granulation tissue,

a hallmark of healthy healing, is described as moist and rough, showing pale pink or bright beefy red depending on depth, while epithelial tissue appears as deep pink as new epidermal cells migrate over the wound surface. A color patch-based method [17] implemented in a clinical setting allowed sequential tracking of wound healing in secondary intention. By correcting for variations in lighting and camera angle, the method standardized color comparison, enabling reliable calculation of wound boundaries and tissue types based on color contrast relative to surrounding skin.

Based on the collected knowledge, the following options are proposed as physiological (normal) skin color characteristics – table 10.

Table 10
Physiological Skin Tones

Physiological skin tone	No	Yes
Pale		
Pale-pink		
Bluish-pink		
Pink		
Olive (yellowish)		
Tan (dark)		
Black		
Bronze		

In addition to recording the physiological skin tone, it is also necessary to document pathological skin discoloration around the wound, which is characteristic of a number of conditions that directly affect the speed and quality of wound healing and the course of the healing process.

Therefore, the following visual markers of skin tone under pathological conditions are proposed – table 11.

Table 11
Pathological Skin Discoloration Around the Wound

Pathological skin tone	No	Yes
Pale		
Cyanotic		
Mottled (Marbled)		
Purple		
Brown		
Red		

Yellow
Bronze
Gray
Black

Depending on the development of complications, tissue death, known as necrosis, may occur during wound healing. Necrotic changes in wound tissues negatively affect healing dynamics by significantly slowing down tissue regeneration, promoting infection, and contributing to wound chronicity.

The final stage of wound healing is the scarring and epithelialization phase, during which reparative processes restore the integrity of the skin and form a scar. Successful completion of this phase is critical for restoring both the strength and integrity of the damaged tissue. The resulting scar(s) may present the following visual types of scars – table 12.

Table 12
Visual Markers of the Scar

Type of scar	No			Yes
Hypotrophic				
Normotrophic				
Hypertrophic				
Planimetric characteristics of scars	Numerical value (mm)			
Shape	Linear	Arcuate	Polygonal	
Length				
Width				
Height				
Area				
Perimeter				

The characteristics of the vascular pattern are also of great importance for the visual assessment of the wound and the wound healing process itself. The vascular pattern around the wound is an important diagnostic indicator that helps evaluate the condition of the wound and the surrounding tissues. Studies using optical microangiography in experimental wound models have demonstrated that dilation of collateral vessels and newly forming microvessels around the wound bed occur rapidly during the inflammatory phase, facilitating increased perfusion to support hypoxic tissue[18].

Visual markers of the vascular pattern are important not only for the wound itself but also for the adjacent tissues. The following visual characteristics are proposed – table 13.

Table 13

Visual Characteristics of the Vascular Pattern

Characteristic	No		Yes		
Intensity of visualization	Low		Medium		High
Extent (mm)	Up to 10	Up to 30	Up to 50	≥50	
Color	Pink	Light red	Dark red	Bluish	
Appearance (pattern type)	Reticular	Star-shaped	Patchy		

The presence of a vascular pattern indicates increased blood flow and activation of microcirculation, which is a normal physiological response to injury. However, in some cases, when combined with other clinical signs, it may be a marker of pathological processes such as infection, allergic reactions, venous stasis, microcirculation disorders, lymphangitis, sepsis, trophic disorders, etc. Therefore, the vascular pattern should be assessed only in combination with other wound markers.

A key component of successful wound healing is the formation of granulation tissue. Granulation is the process through which the body generates new connective tissue and blood vessels at the site of injury to the skin or mucous membrane. Therefore, visualization of granulation tissue is a critical part of assessing wound status. The following visual markers of granulation tissue are proposed – table 14.

Table 14

Visual Markers of Granulation Tissue

Characteristic	No		Yes		Details / Options				
Presence of granulation tissue									
Color									
New capillaries			Pale	Pale pink	Bright pink	Red	Bluish	Gray	Black
Immature granulation tissue									
Mature granulation tissue									
Hypergranulation									
Fibrous granulation									

Infected granulation

Necrotic granulation

The set of the above tables forms the general view of the scale of visual characteristics of an aseptic wound.

3.3. Rationale for building an ontology of aseptic wounds

Despite the availability of a wide range of visual characteristics of wounds, the lack of a formalized model that would describe the relationships between these features greatly complicates their integration into intelligent medical systems. To overcome this problem, it is advisable to create a wound ontology - a structured representation of concepts, their attributes, types of relationships, and the hierarchy that exists between them.

The ontology allows for semantic interoperability between different data sources, medical applications, and machine learning algorithms [19, 20]. The wound ontology helps to unify terminology, improve data exchange between systems, and generate queries to search for or classify wound conditions.

In the context of the development of intelligent diagnostic and remote monitoring systems, the ontological model of wounds is becoming a key basis for the development of knowledge-based platforms that support automated clinical decision-making. In particular, it allows you to link visual signs to clinical scenarios, healing phases, and prognosis.

As part of our study, we formed a primary prototype of the aseptic wound ontology based on the proposed system of visual markers. This prototype describes the basic concepts, such as types of injuries, planimetric parameters, topographic characteristics, phase signs of healing, and establishes logical and functional relationships between them. To build the ontology of the subject area "Aseptic Wound", the Protégé tool environment [21] was used. Protégé is one of the most common freeware tools with a large number of plugins for creating, visualizing and editing ontologies, supporting the OWL and RDF standards, and also provides the implementation of reasoning (Reasoner) [22]. The ontology was implemented in the OWL format [23], which allows for a clear description of classes, properties, relations between concepts, constraints and logical rules. The OWL language is currently the most common ontology language in the world, including for the semantic Web with formally defined DL (Description Logic) values (IDEF5 standard for describing ontologies [24, 25]). The structuring of classes was carried out in accordance with the conceptual model developed on the basis of an expert survey. A bottom-up approach was used in the construction process - from the formalization of individual features and characteristics to generalization in a hierarchy of concepts. This allowed the use of a set of OWL operators to organize the taxonomy of aseptic wounds.

The conceptual model of the aseptic wound ontology (Figs. 1, 2) is the basis for the development of intelligent systems capable of working with expert data, conducting semantic analysis, providing accurate and understandable interpretation of wound images, and generating recommendations for further treatment. The use of Protégé provided the ability to check the ontology's consistency, visualize it, and further integrate it with other medical information systems or artificial intelligence modules.

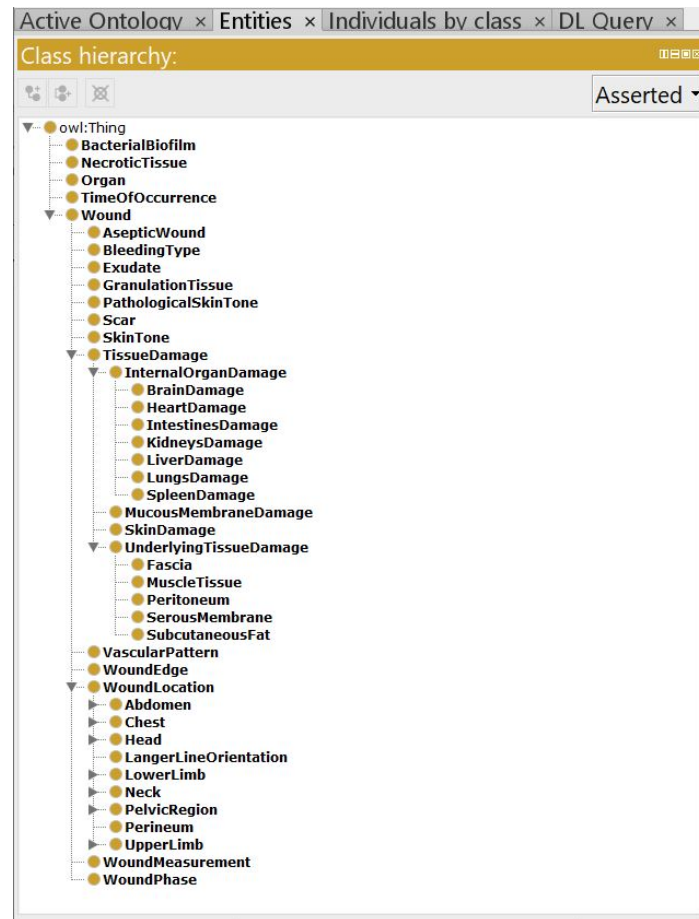


Figure 2: A snippet of the Ontology of Aseptic Wounds.

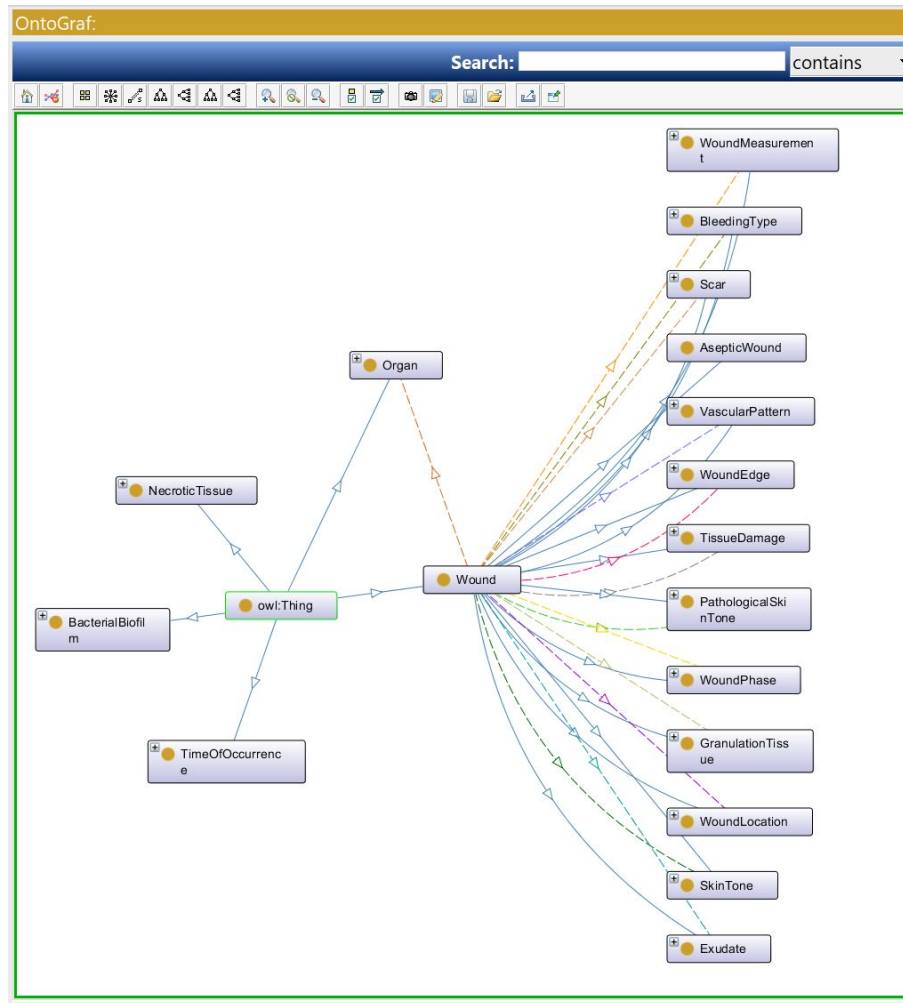


Figure 3: A Fragment of Ontograph of Ontology of Aseptic Wounds.

4. Discussion

The proposed methodology for assessing an aseptic wound made it possible to develop a hierarchically ordered structure of visual characteristics that covers both static morphometric features and dynamic changes in the healing process. Based on this, a basic version of the aseptic wound ontology was formed, which allows not only to formalize terminology but also to ensure interoperability between different information sources and clinical systems.

The use of an ontological model allows generalizing and unifying the process of visual description of wounds, as it links visual parameters (shape, size, type of tissue damage), phase characteristics (inflammation, proliferation, remodeling), type of bleeding, presence of a film or discharge, as well as scarring and skin color. This allows artificial intelligence systems to effectively classify and predict the course of the wound process.

Planimetric and morphological characteristics were tested to form descriptors of the visual model within the prototype ontology. The established intercategory relationships (e.g., between wound localization, planimetry, and potential complications) became the basis for building rules in logical computing modules.

Thus, the created model not only allows for standardizing the process of diagnostic description of an aseptic wound, but also ensures its machine interpretability, which is critical for integration into clinical information systems and decision support systems.

The proposed methodology has several limitations. The developed ontology is based primarily on expert knowledge and theoretical modeling, with limited validation using real-world clinical datasets. Similar to [26], the model has not yet been comprehensively tested across diverse clinical environments, imaging modalities, or patient populations, which may limit its generalizability. The current version of the ontology does not incorporate multi-modal data such as advanced imaging, histological data, or biochemical markers, which could provide additional dimensions for AI-based wound assessment. Additionally, while the ontology was designed with machine interpretability in mind, its integration with actual deep learning architectures and clinical decision support systems has not yet been fully implemented or evaluated.

Future research should focus on expanding and refining the ontology using large-scale annotated datasets derived from real clinical images of aseptic wounds. Special attention should be given to the formal alignment of the ontology with existing biomedical standards such as SNOMED CT (Systematized Nomenclature of Medicine – Clinical Terms), FMA (Foundational Model of Anatomy), or ICD (International Classification of Diseases), to ensure semantic interoperability with electronic health records. Additionally, efforts should be made to embed the ontology within AI training pipelines, especially in convolutional neural networks and explainable AI frameworks, to evaluate its practical utility in image classification, segmentation, and prognosis prediction tasks. Further development will also involve the extension of the model to include infected, chronic, or post-traumatic wounds, thereby creating a comprehensive ontology capable of supporting intelligent wound management systems across the full spectrum of wound types.

5. Conclusions

The developed conceptual methodology for visual assessment of aseptic wounds opens up new opportunities for the integration of digital technologies into the practice of surgical diagnosis and monitoring of the wound process. Due to their predictable and uniform healing trajectory, aseptic wounds constitute an optimal reference framework for the initial training of AI models focused on wound assessment, enabling the recognition of typical regenerative features before extending model capabilities to pathological or non-standard healing scenarios.

The proposed ontological model allows formalizing the key visual characteristics of wounds, providing their unified representation for artificial intelligence systems. The use of structured descriptors and cross-category relationships helps to improve the accuracy of automated wound assessment and wound healing prediction. The results of the study can be applied both in clinical practice and to create training samples for medical AI systems, which makes the proposed approach a promising direction in the development of digital medicine.

Declaration on Generative AI

The author(s) have not employed any Generative AI tools.

References

- [1] C. Wang, D. Anisuzzaman, V. Williamson, et al. "Fully automatic wound segmentation with deep convolutional neural networks." *Scientific Reports* 10(21897), 2020. URL: <https://www.nature.com/articles/s41598-020-78799-w>
- [2] H. Carrión, M. Jafari, MD. Bagood, H. Yang, R. Isseroff, M. Gomez, Automatic wound detection and size estimation using deep learning algorithms, *PLoS Comput Biol* 18(3): e1009852 (2022). doi:10.1371/journal.pcbi.1009852.

- [3] M. Wierzbicki, B. Jantos, M. Tomaszewski, A Review of Approaches to Standardizing Medical Descriptions for Clinical Entity Recognition: Implications for Artificial Intelligence Implementation, *Applied Sciences* 14(21):99032024 (2022). doi:10.3390/app14219903.
- [4] K. Borys, Y. Schmitt, M. Nauta, C. Seifert, N. Krämer, C. Friedrich, F. Nensa, Explainable AI in medical imaging: An overview for clinical practitioners–Beyond saliency-based XAI approaches, *European journal of radiology* 162, 110786 (2023).
- [5] S. P. Choy, et al. Systematic review of deep learning image analyses for the diagnosis and monitoring of skin disease, *NPJ Digital Medicine* 6.1 (2023): 180.
- [6] M. Myslicka, et al. Review of the application of the most current sophisticated image processing methods for the skin cancer diagnostics purposes, *Archives of Dermatological Research* 316.4 (2024): 99.
- [7] Sven van Poucke and Woundontology Consortium. URL: <https://www.slideshare.net/slideshow/woundontology1/424644#24>.
- [8] Gene Ontology Consortium, Wound healing (GO:0042060). URL: <http://PMC+4informatics.jax.org+4informatics.jax.org+4>.
- [9] Ontology for Biomedical Investigations (OBI). URL: <http://obi-ontology.org/>.
- [10] E. Haesler, et al. A systematic review of the literature addressing asepsis in wound management, *Wound Practice & Research: Journal of the Australian Wound Management Association* 24.4 (2016): 208-216.
- [11] E. Purssell, R. Gallagher, D. Gould, Aseptic versus clean technique during wound management? Systematic review with meta-analysis, *International journal of environmental health research* 34.3 (2024): 1580-1591.
- [12] V. Borst, A. Riedmann, T. Dege, K. Müller, A. Schmieder, B. Lugin, S. Kounev, WoundAIssist: A Patient-Centered Mobile App for AI-Assisted Wound Care With Physicians in the Loop 2506.06104 (2025).
- [13] H. Carrión, M. Jafari, H. Yang, R. Isseroff, M. Rolandi, M. Gomez, N. Norouzi, Healnet-self-supervised acute wound heal-stage classification, In *International Workshop on Machine Learning in Medical Imaging*, Cham: Springer Nature Switzerland (2022): 446-455.
- [14] M. Rochon, J. Tanner, J. Jurkiewicz, J. Beckhelling, A. Aondoakaa, K. Wilson, L. Dhooonmoon, M. Underwood, L. Mason, R. Harris, K. Cariaga, Wound imaging software and digital platform to assist review of surgical wounds using patient smartphones: The development and evaluation of artificial intelligence (WISDOM AI study), *PloS one*, 19(12), e0315384 (2024). doi.org/10.1371/journal.pone.0315384.
- [15] L. Dudgeon, P. G. Sargent, The Bacteriology of Aseptic Wounds, *The Lancet* 168.4342, pp. 1335-1341.
- [16] S. Chairat, S. Chaichulee, T. Dissaneewate, P. Wangkulangkul, L. Kongpanichakul, AI-Assisted Assessment of Wound Tissue with Automatic Color and Measurement Calibration on Images Taken with a Smartphone. *Healthcare*, 11(2), 273 (2023). doi:10.3390/healthcare11020273.

- [17] S. Yang, J. Park, H. Lee, S. Kim, B. Lee, K. Chung, B. Oh, Sequential Change of Wound Calculated by Image Analysis Using a Color Patch Method during a Secondary Intention Healing, PloS one, 11(9), e0163092. doi:10.1371/journal.pone.0163092.
- [18] K. Leiva, A. Trinidad, I. Gonzalez, A. Espinosa, T. Zwick, J. Levine, M. Rodriguez, H. Lev-Tov, W. Wu, R. Kirsner, A. Godavarty, Development of a Tissue Oxygenation Flow-Based Index Toward Discerning the Healing Status in Diabetic Foot Ulcers, *Advances in wound care* 13(1) (2024): 22–33. doi:10.1089/wound.2022.0170.
- [19] S. Lupenko, V. Pasichnyk, N. Kunanets, O. Orobchuk, M. Xu, The Axiomatic-Deductive Strategy of Knowledge Organization in Onto-based e-learning Systems for Chinese Image Medicine, in: The 1st International Workshop on Informatics & Data-Driven Medicine, Lviv, Ukraine, 2018, pp.126-134.
- [20] S. Lupenko, O. Orobchuk, M. Xu, The Ontology as the Core of Integrated Information Environment of Chinese Image Medicine, Vol. 938, *Advances in Computer Science for Engineering and Education II*, 2019, pp. 471-481.
- [21] The Protégé Ontology Editor and Knowledge Acquisition System. URL: <http://protege.stanford.edu/>.
- [22] I. Horrocks, Owl: A description logic based ontology language, *International conference on principles and practice of constraint programming*. URL: https://link.springer.com/chapter/10.1007/11564751_2.
- [23] OWL Web Ontology Language Guide. W3C Recommendation. URL: <http://www.w3.org/TR/owl-guide/>.
- [24] Ontology Description Capture Method. URL: <http://www.idef.com/idef5-ontology-description-capture-method/>.
- [25] Peraketh, Benjamin, et al. Ontology Capture Method (IDEF5). No. ALH RTP19940029. URL: <https://apps.dtic.mil/sti/tr/pdf/ADA288442.pdf>.
- [26] L. Dao, N. Ly, Ontology-based knowledge representation for bone disease diagnosis: a foundation for safe and sustainable medical artificial intelligence systems, (2025). URL: <https://arxiv.org/abs/2506.04756>.