

# Ultrasound Volume Based Surgical Planning for Prosthesis Implantation in the Shoulder Joint

Ute v. Jan<sup>1</sup>, Dennis Sandkühler<sup>2</sup>, Ludger Kirsch<sup>3</sup>,  
Heinrich Martin Overhoff<sup>2</sup> and Oliver Rühmann<sup>3</sup>

<sup>1</sup>Institute of Medical Informatics, Hannover Medical School, D-30625 Hannover

<sup>2</sup>Medical Engineering Laboratory,  
University of Applied Sciences, D-45877 Gelsenkirchen

<sup>3</sup>Orthopedic Department, Hannover Medical School, D-30625 Hannover  
Email: jan.ute.von@mh-hannover.de

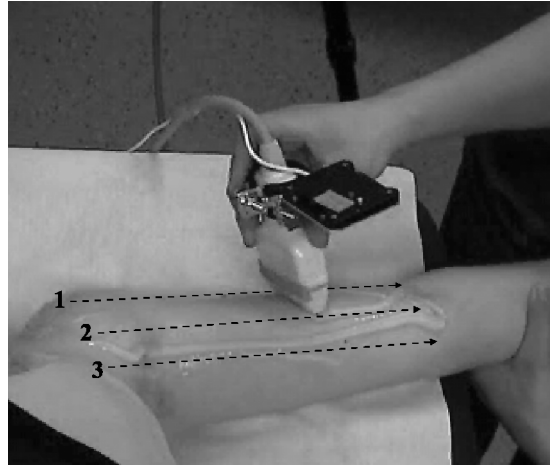
**Abstract.** Surgical planning for the implantation of a prosthesis in the shoulder joint is at present usually done using CT, MRI and X-ray imaging. Apart from being expensive and hard to use in some settings, modalities like CT and X-ray additionally expose the patient to ionizing radiation. In comparison, ultrasound is an easy to use, cheap modality. By combining a conventional two dimensional probe with a localizer system, even larger anatomical structures like the humerus can be examined and delineated using ultrasound. In a pilot study, we investigated the use of such three-dimensional volumes for surgical planning in the shoulder joint.

## 1 Introduction

Current diagnostics and surgical planning methods for determining the necessary geometric parameters for the implantation of a prosthesis in the shoulder joint are mainly X-ray, CT and MRI based. These imaging modalities give a complete representation of the joint's geometry, and CT resp. MRI even make it possible to determine three-dimensional (3-D) measures. Ultrasound imaging offers alternative options, as it avoids ionizing radiation, is easy to use in a pre- and intra-operative set up, and is cheap. On the other hand, conventional sonography only yields two-dimensional sector images and thus allows only for a small field of view on the three-dimensional anatomy. Additionally, it often generates blurred images, which can also show artifacts. Therefore, ultrasound imaging of the shoulder joint is at present mostly employed for diagnostic purposes, where the images are only acquired in certain standardized orientations [1], and the identification of certain anatomical landmarks places high demands on the physician's experience.

In this context, finding the correct position for humeral part of the shoulder prosthesis solely based on ultrasound images seems only to be possible if 2-D ultrasound is extended to a 3-D imaging modality, and if the images are analyzed using an automatic, computer-based approach to avoid misleading interpretation. The (segmented) image data should contain all landmarks that are necessary to determine the correct shape and location of the prosthesis.

**Fig. 1.** A three-dimensional ultrasound volume is generated by the superposition of sequentially (1-3) acquired sub-volumes.



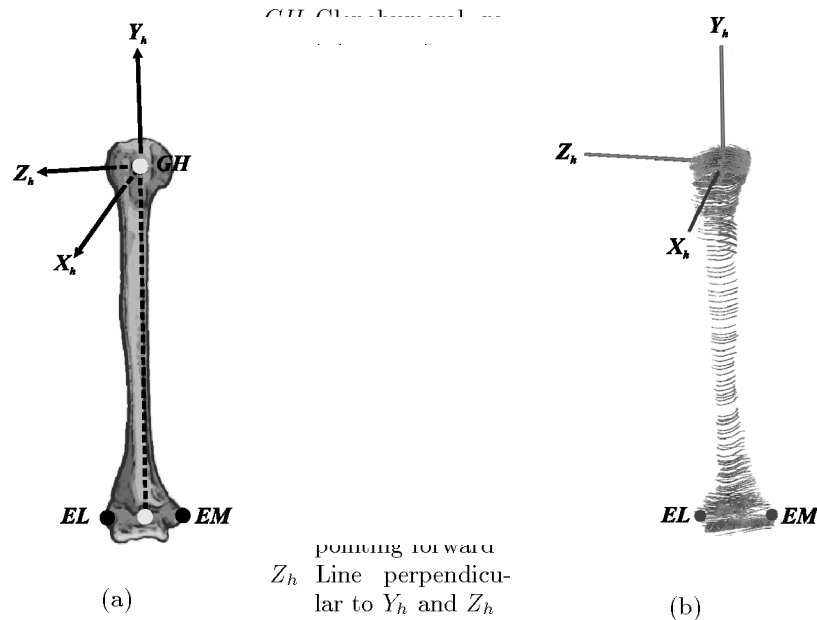
In this pilot study, we investigated how a three-dimensional ultrasound image volume of the humerus can be acquired that contains all relevant anatomical landmarks. We also developed a software for a semi-automatically generated visualization of the surface of the humerus, which is used for an interactive landmarks-based prosthesis implantation planning.

## 2 Material and Methods

$N = 20$  three-dimensional ultrasound image volumes of the humeri of healthy volunteers were recorded as manually controlled freehand sweeps (with the arm placed in a fixed position: slightly abducted, external rotation) using a conventional ultrasound system (Nemio<sup>TM</sup> SSA-550A, Toshiba, Tokyo, Japan) with an infrared optical localizer system (Polaris<sup>TM</sup>, Northern Digital Inc., Waterloo, Ontario, Canada) fixed to the scanhead. Image and position data were recorded simultaneously on a standard PC (Intel Pentium<sup>TM</sup> IV, 3.2 GHz, 512MB RAM). All further steps were also performed on this PC.

As ultrasound waves do not penetrate bone, it is not possible to record an entire bone's surface at once. To acquire a complete ultrasound volume, a procedure was developed to collect several overlapping sub-volumes (each containing about 200-300 slices). For each sub-volume, the image data acquisition is performed by moving the scanhead from the top of the humeral head down to the elbow region, the next sub-volume is then recorded with a slight lateral offset to the previous one (fig. 1). After segmentation, the sub-volumes are registered to one another. The segmented and registered sub-volumes form an almost complete and anatomically correct representation of the surface of the humerus.

**Fig. 2.** Local coordinate system (LCS) for the humerus as defined by the International Shoulder Group [2]. (a) schematic drawing (anterior view), (b) LCS derived from the positions of the bony landmarks determined from the segmentation results

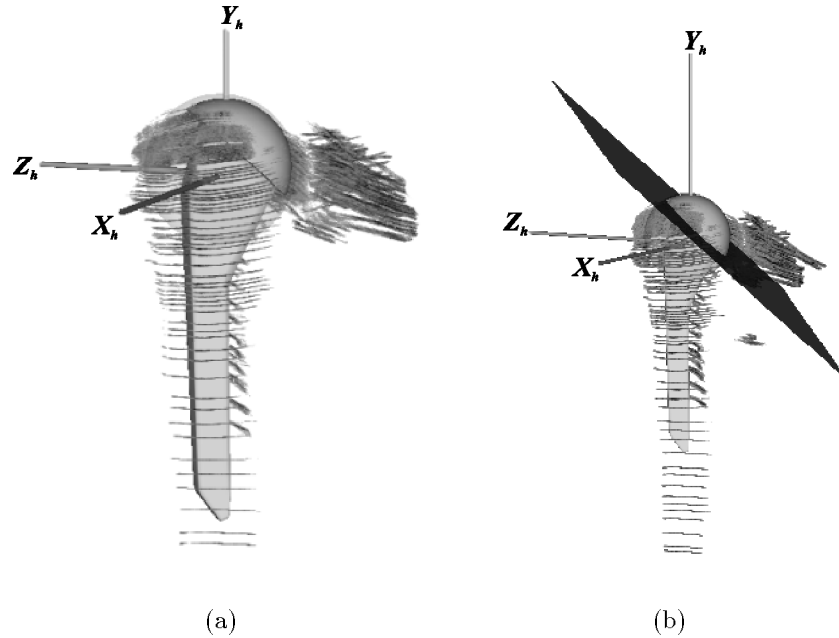


Segmentation is done using a semiautomatic, locally adaptive process based on classes made available through the Insight Toolkit (ITK) library. Within an interactively defined region of interest roughly approximating the bone's surface, the bony structures are delineated automatically. The segmentation process takes about 4-5 minutes for a volume containing about 1000 slices.

From the segmented image data, i.e. the representation of the humerus surface, a local coordinate system (LCS) of the humerus is derived in accordance with the specification of the International Shoulder Group (ISG) [2]. This coordinate system is used as a reference for all further parameters for the implantation.

The humeral head closely resembles a sphere, but not all of the surface's points can be seen within an ultrasound volume due to the anatomical circumstances, e.g. the top of the humeral head being covered by the acromion. Therefore, a robust approximation algorithm – e.g. as described in [3] – has to be applied to the segmented data of the head region to determine the parameters for an appropriate sphere. The center of this sphere is used as an estimation of the glenohumeral rotation center. Together with the coordinates for the most prominent points on the lateral and medial epicondyle, which are also determined from the segmented ultrasound volume, the sphere's center is used as a basis to reconstruct the humerus LCS (fig. 2) as defined by the ISG.

**Fig. 3.** Segmentation results overlaid with the sphere approximating the humeral head and the prosthesis (a) as well as the resection plane (b). The location of resection plane and prosthesis are documented relatively to the local humerus coordinate system.



According to several groups [4, 5], morphometric studies of the humerus show an enormous inter-individual variation of the proximal anatomy of the humeral head. Modern so-called 3<sup>rd</sup> and 4<sup>th</sup> generation humerus prostheses allow a precise anatomical reconstruction of these individual variations. To determine the correct placement of those prostheses, not only the inclination of the head, but also the posterior and medial offset as well as the individual's retrotorsion have to be taken into account [6]. Therefore, several additional landmarks on the humerus (e.g. an approximation of the collum anatomicum and the intertubercular sulcus) are determined semiautomatically - i.e. the automatically determined approximate position is interactively fine-tuned by the physician. These landmarks are then used to correctly identify the necessary parameters for the resection plane used for the humeral head. The location of the additional landmarks and the humerus prosthesis are documented relative to the humerus LCS.

### 3 Results

All acquired image volumes could be reasonably segmented. In cases where the segmentation of the bony structures on a slice was unsure, e.g. due to a blurred representation of the bone's surface owing to the scanhead's inclination, the

results for that slice were left out to avoid falsely-positive delineations of the humerus surface. This procedure did not present a problem with the completeness of the virtual humerus model due to the large number of slices in each volume.

Using the resulting three-dimensional representation of the humerus, the landmarks necessary for the placement of the resection plane could be interactively identified. The segmentation results as well as the landmarks and the resection plane could be interactively visualized (fig. 3) using an application based on the Visualization Toolkit (VTK). A model of the humeral part of the prosthesis can also be overlaid to give a more intuitive insight into the planned scenario.

## 4 Discussion

For the investigated volunteers, it could be shown that a purely ultrasound image-guided virtual interactive implantation of a humerus prosthesis is feasible. To review the validity of the determined landmarks and the placement of the resection plane, a cadaver study is planned. Future work also needs to be done on identifying all landmarks fully automatically. This would simplify the interactive placement of the prosthesis and would also potentially lead to a more investigator-independent surgical planning process.

## References

1. Konermann W, Gruber G. *Ultraschalldiagnostik der Stütz- und Bewegungsorgane*. Stuttgart, New York: Thieme; 2000.
2. van der Helm FCT, Makhsous M, van Roy P, Anglin C, et al. ISB recommendation on definitions of joint coordinate system of various joints for the reporting of human joint motion – part II: Shoulder, Elbow, Hand and Wrist. *J Biomech* in press;.
3. Overhoff HM, Ehrich S, von Jan U. Reliable identification of sphere-shaped femoral heads in 3-D image data. In: Henson KennethM, editor. *Medical Imaging 1999: Image Processing*. vol. 3661 of *Procs SPIE*; 1999. p. 1377–1387.
4. Kunz C, Rieder T, Viehweger R. Can ultrasonography be used to measure torsion angle of the humerus? *Z Orthop Ihre Grenzgeb* 1993;131:307–312.
5. Pearl ML, Kurutz S. Geometric Analysis of Commonly Used Prosthetic Systems for Proximal Humeral Replacement. *J Bone Joint Surg Am* 1999;81-A(5):660–671.
6. Boileau P, Walch G. The three-dimensional geometry of the proximal humerus. Implications for surgical technique and prosthetic design. *J Bone Joint Surg Br* 1997;79(5):857–65.