

Fast Detection and Processing of Arbitrary Contrast Agent Injections in Coronary Angiography and Fluoroscopy

Alexandru Condurache¹, Til Aach¹, Kai Eck² und Joerg Bredno²

¹Institute for Signal Processing, University of Luebeck, 23538 Luebeck, Germany

²Philips Research Laboratories, 52066 Aachen, Germany

Email: condura@isip.uni-luebeck.de

Abstract. Percutaneous transluminal coronary angioplasty (PTCA) requires both pre-interventional cine-angiograms showing the contrasted vessel tree over several heart cycles, and live X-ray monitoring (fluoroscopy) during the catheterization. Navigation during the intervention can be facilitated by fusing the automatically synchronized cine-angiogram with the interventional images, e.g. by overlaying the synchronized angiogram over the interventional images. Clearly, this fusion should be limited to those frames of the angiogram which show the full contrasted vessel tree. Conversely, if contrast agent appears in the fluoroscopy images, overlay is not required and should be switched off. To these ends, we describe approaches for the detection and processing of contrast agent injections in cardiac X-ray image sequences.

1 Introduction

Treatment of coronary heart disease needs both pre-interventional and interventional X-ray images. In the pre-interventional coronary angiograms, a radio-opaque contrast agent injected into the coronaries serves to make the respective part of the arterial tree visible. The angiograms is recorded and used for diagnosis of, e.g., stenoses, and as roadmap for the subsequent catheterization procedure. During the intervention, a catheter or a guide-wire is advanced under X-ray monitoring (fluoroscopy) through the vessels to the lesion. During this procedure, contrast may only be given in occasional bursts. To help navigation, a single frame showing the entire vessel tree filled with contrast agent is selected manually from the pre-interventional angiogram and displayed as roadmap on a screen next to the interventional fluoroscopy images. This static roadmap image is, however, generally not consistent with the instantaneous heart and respiration movements in the fluoroscopy images.

To improve guidance during catheter placement, we developed methods to overlay motion compensated roadmap information from the angiogram onto the fluoroscopic images [1] (cf. also [2]). This fusion of pre-interventional and interventional data should be restricted to those frames of the pre-interventional coronary angiogram in which the complete vessel tree is filled by contrast agent

(“filled state”, [3]). Furthermore, the selected and geometrically pre-processed roadmap has to be enhanced to allow the simultaneously overlaid display of roadmap and fluoroscopy image on one screen. When a burst of contrast agent appears in the interventional images, the overlay should be switched off since the vessels are then visible in the interventional data.

In [3], we have described two-step algorithms to identify and separate the “filled state”-frames in angiograms from the inflow and washout phases of the contrast agent. In the first step, contrasted vessels are enhanced and background is equalized. From the resulting vessel maps, a histogram-based feature is calculated. Analysis of the behavior of this feature over frame index (i.e. time) yields the “filled-state”-frames.

In this paper, we focus on the detection of contrast agent in fluoroscopy images. Unlike for pre-interventional angiograms which can be processed off-line, interventional image analysis requires a strictly causal processing. Furthermore, fluoroscopy images are acquired with less dose than angiograms, and therefore exhibit a lower signal-to-quantum noise ratio [4].

As for angiograms, we first compute a vessel feature map such that its histogram can be assumed to consist of two distributions, one from background and one from potentially occurring contrasted vessels. To make these distributions as disparate as possible, we seek to equalize non-vessel background information, thus reducing its standard deviation. The additional absorption of contrasted vessels is then transformed such that its mean is considerably larger than the background mean. Since we seek to detect the presence of contrast agent from the vessel map histograms rather than accurate segmentation or enhancement geared towards the human observer, issues like border accuracy and preservation of a certain “harmony” in the processed images are of less concern [5,6,7].

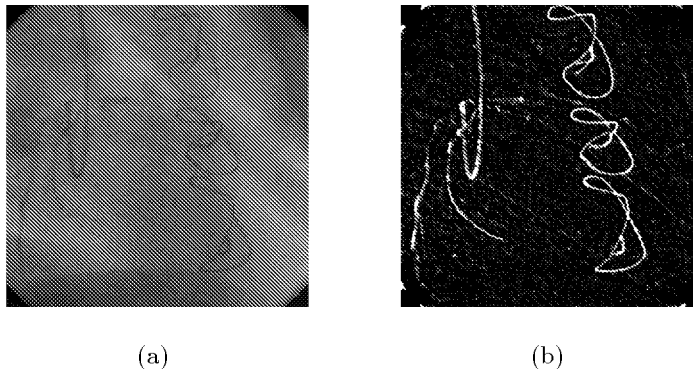
Since enhanced contrasted vessels show up with high intensities in the vessel maps, we analyse their histograms and use the 98-percentile as a measure of presence of contrast agent. In the beginning, our algorithm first learns how the 98 percentile behaves when no contrast agent is given (null hypothesis). It then sets a threshold for the percentile via a significance test [8]. If the 98 percentile obtained for frames after the learning phase is larger than the threshold, they are classified as containing contrast agent.

2 Feature Extraction

2.1 Vessel Enhancement

In order to equalize (or “flatten”) background, the interventional frame is tophat-filtered [9,10]. A tophat-filter first removes vessels — which always absorb stronger than their immediate neighbourhood [5] — by a local sliding maximum filter followed by a local minimum. The result is subtracted from the original, yielding predominantly vessel information. The size of the sliding window is chosen such that it slightly exceeds the diameter of the largest vessel sought to be preserved. Optionally, vessel motion may be used for further enhancement:

Fig. 1. Original interventional frame (a), showing partly contrasted vessels, a catheter, a guide wire and sewing wires, and its vessel map (b).



In the pixel-wise differences between the current tophat-filtered image and its tophat-filtered predecessor, clipping the positive values and adding the result to the current tophat-filtered image tends to increase the contrast for locally dark, moving structures, i.e. vessels. A subsequent gradient-magnitude operation applied to the tophat-filtered images responds to the slopes at vessel borders. This operator is additively complemented by a second-derivative filter in the form of a difference-of-Gaussians (DoG), which responds to the middle of the vessels. Finally, to compensate the blurring of vessel boundaries introduced by the finite-sized derivative operators, we then multiply the vessel-filtration result with the grey-level inverted tophat-filtered image in which the boundaries are better preserved. A result is shown in **Fig. 1**.

2.2 Histogram Based Feature and Feature Curve

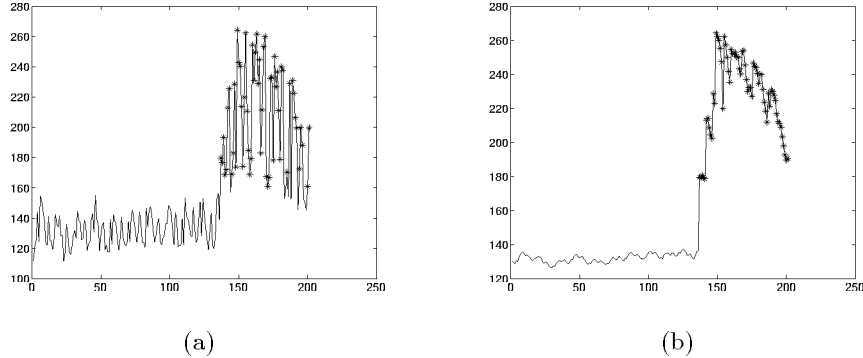
We seek a feature related to the surface covered by contrasting vessels, which is robust with respect to noise as well as to other ever-present, vessel-like structures like sewing wires. While ideally one would analyse the maximum grey level, the 98-percentile of the histogram is such a robust feature. The evolution of this vessel surface-linked feature over frame index generates a feature curve (**Fig. 3(a)**), where the frames with contrast agent can already visually be easily identified. Since we must decide on the presence of contrast agent based on past frames only, we apply a causal recursive first-order low-pass filter to this curve. The filtered curve is shown in **Fig. 3(b)**. The difference equation characterizing this filter is:

$$y(n) = ax(n) + (1 - a)y(n - 1) \quad (1)$$

where:
$$\begin{cases} 0 < a < 1 & \text{if } x(n) - x(n - 1) \leq 4\sigma_0(x) \\ a = 1 & \text{else} \end{cases}$$

where $\sigma_0(x)$ is the standard deviation estimated for the null hypothesis from the first frames of the sequence. The filter thus smoothes within stationary time intervals, but preserves what it assumes to be a transition.

Fig. 2. Initial feature curve a) and feature curve after filtration b). Also the segmentation results are shown. Detected contrast burst frames are marked with stars.



3 Feature Curve Segmentation

From the learning phase, over the first contrast agent-less seconds of the intervention, we can describe the distribution $p(y(n)|H_0)$ of the unfiltered or filtered feature $y(n)$ given the null hypothesis H_0 by a Gaussian with estimated mean μ_0 and variance σ_0^2 . As **Fig. 2** illustrates, detection of frames with contrast agent is possible by thresholding the feature curve. Ideally, finding the optimal threshold requires feature distributions for both null hypothesis and opposite hypothesis H_1 . Practically, we can only estimate the parameters for H_0 , and therefore set the threshold by a significance test. The threshold T is determined such that the probability of $y(n)$ exceeding T given H_0 is α , which is the so-called significance level, which is equivalent to the false positive rate. T is thus given by inverting $\Pr(y(n) > T|H_0) = \alpha$ based on $p(y(n)|H_0)$. Whenever the (filtered) 98-percentile $y(n)$ exceeds this threshold, the corresponding frame is classified as containing contrast agent.

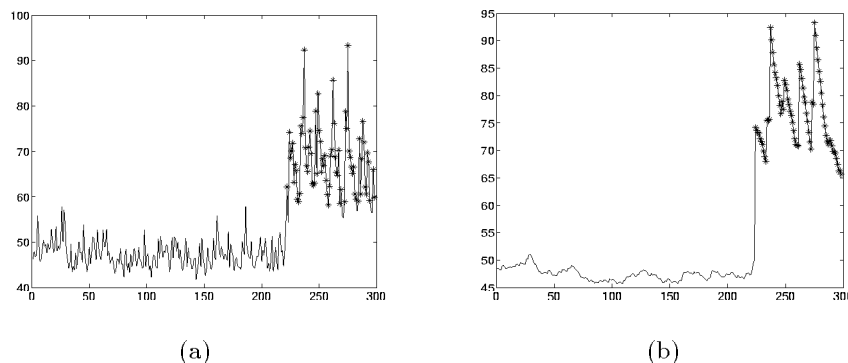
4 Results

We have processed a total of six sequences recorded during catheter interventions. All sequences have been processed with the same parameter set both for the computation of the vessel map (cf. [3]) and for the significance test. The parameters μ_0 and σ_0^2 are estimated from the first 70 interventional images. The significance level was determined empirically, and set to $\alpha = 10^{-4}$ for the recursively filtered percentile feature. **Fig. 2** and **Fig. 3** show the segmentation results for two of the sequences in our data base. It may be observed that the segmentation results improve once the IIR low-pass filter is applied.

5 Discussion

As a complement to an earlier algorithm to identify contrasted frames in angiograms [3], we have described methods for the identification of cardiac fluo-

Fig. 3. Segmentation results on the initial a) and filtered b) feature curve for a sequence in our data base. Detected contrast burst frames are marked with stars.



roscopy images showing contrast agent bursts. In a first step, vessel information is enhanced and non-vessel background flattened. A histogram-based feature is then derived, which is thresholded. The threshold is set by a significance test. Initial tests on routine clinical data gave satisfactory results, even in the presence of other vessel-like structures, like sewing wires. Further tests on a demonstrator in a clinical environment are envisaged [11].

References

1. B.Martin-Leung, K.Eck, I.Stuke, et al.: Mutual information based respiration detection. Proc. CARS:1085–1092, 2003.
2. D.W.Ro, L.Axel, G.T.Herman, et al.: Computed masks in coronary subtraction imaging. IEEE Trans Med Imaging, 6(4):297–300, 1987.
3. T.Aach, A.Condurache, K.Eck, et al.: Statistical-model based identification of complete vessel-tree frames in coronary angiograms. to appear in Electronic Imaging, 5299, 2004.
4. T.Aach, U.Schiebel, G.Spekowius: Digital image acquisition and processing in medical x-ray imaging. J Electronic Imaging, 8:7–22, 1999.
5. T.Aach, C.Mayntz, P.Rongen, et al.: Spatiotemporal multiscale vessel enhancement for coronary angiograms. Med Imaging 4684:1010–1021, 2002.
6. Z.Chen, S.Molloi: Multiresolution vessel tracking in angiographic images. Comp Med Imaging and Graph, 26:419–428, 2002.
7. A.F.Frangi, W.J.Niessen, K.L.Vincken, et al.: Multiscale vessel enhancement filtering. Med Image Comput and Comp-Assisted Interv, 1496:130–137, 1998.
8. A.Papoulis: Probability & Statistics. Prentice-Hall International, Englewood Cliffs, 1990.
9. E.R.Dougherty: Math Morphology in Image Processing. Marcel Dekker, New York, 1992.
10. M.Pakura, O.Schmitt, T.Aach: Segmentation and analysis of nerve fibers in histologic sections of the cerebral human cortex. 5th IEEE Southwest Symp on Image Analysis and Interp:62–66, 2002.
11. J.Bredno, B.Martin-Leung, K.Eck: Software architecture for live enhancement of medical images. to appear in Electronic Imaging 5297, 2004.